The Use of Active *Leptospermum* Honey on Difficult to Heal Wounds of Various Etiologies.

Nancy Chaiken, ANP-C, CWOCN
Swedish Covenant Hospital, Chicago, IL

INTRODUCTION

Clinicians who treat wounds must choose from a plethora of advanced wound care dressings and treatment modalities to address the changing wound environment. When a wound stalls, dressings are selected to address the root cause of non-healing. The therapeutic effects of Active *Leptospermum* Honey (ALH) for chronic, non-healing wounds, have been well documented. ALH has anti-inflammatory[1] and anti-bacterial properties[2], promotes autolytic debridement[3, 4] and increases the velocity of healing[4, 5]. The combination of these properties in one dressing may be beneficial for wounds of atypical origin, especially when inflammation, bio-burden, and necrotic tissue delay healing.

PURPOSE/RATIONALE

Since ALH has multiple properties that address many common, underlying causes of non-healing wounds, it was chosen for use on several wound types toevaluate its therapeutic effects. The dressing was used on three patients with multiple co-morbidities and wounds of differing etiologies including: pyoderma gangrenosum, rheumatoid ulceration, and a stage IV sacral pressure ulcer. The presence of one or more wounds was causing great pain and discomfort for each patient.

METHODOLOGY

Three patients presenting with chronic non-healing wounds of varying etiologies were selected to receive ALH dressings for their reported anti-inflammatory, antibacterial, and debriding effects. ALH Dressings were applied, covered with an absorbent cover dressing, and changed daily, every other day, or more frequently if needed for strike through.

ANTI-INFLAMMATORY AND IMMUNOMODULATORY EFFECT

Honey stimulates human monocytic cells which produce inflammatory cytokines that have an important role in the resolution of infection and repair of tissue. An observed effect of honey on cytokine production in myeloid cells isunrelated to bacterial contamination or endotoxins; rather they are specifically related to a 5.8kDa moiety isolated from the *Leptospermum* species honey. Inflammatory responses in monocytes via an interaction with TLR4 have been stimulated by this component[1].

ANTI-MICROBIAL EFFECT

ALH possesses florally derived antibacterial activity[6] and the ability to inhibit the growth of multiple organisms including *Methicillin resistant staphylococcus aureus* (MRSA), *Vancomycin resistant enterococcus, Pseudomonas aeruginosa,* and *Beta-hemolytic streptococci* have been documented[2].

DEBRIDEMENT EFFECT

The mechanism of action for ALH's debriding effects includes both autolysis and osmosis. The dressing provides a moist environment, aiding the body's own process of autolysis[3]; the high sugar content of ALH promotes movement of fluid from an area of greater concentration to an area of lower concentration, drawing lymph fluid to the surface of the wound resulting in a pooling, or osmotic effect, which bathes the wound[7]. Additionally, circulating plasminogen in the lymph fluid is likely converted to the enzyme plasmin which disturbs the adherent bonds tethering necrotic tissue to the wound bed[8].

OUTCOME

In each case significant wound improvement was noted as demonstrated by decreased inflammation and pain, decreased slough, and increased healing. ALH dressings were easy to use, economical, effective, and well tolerated by each patient, subsequently improving life quality.

CONCLUSION

Choosing appropriate dressings and treatment modalities for individuals with chronic, non-healing wounds, is challenging due to many underlying, causative factors. The use of dressings with ALH simplified the decision process. The dressings demonstrated the ability to decrease inflammation and pain, clear slough, and increase healing in this group of patients with multiple co-morbidities and the following wound types: pyoderma gangrenosum, rheumatoid arthritis, and a stage IV pressure ulcer. As a result, ALH has become this clinician's product of choice when there is a need to address the changing wound environment and multiple underlying causes of non-healing wounds. Further studies are indicated.

References:
1. Tonks, A.J., et al. (2007) *A 5.8-kDa component of manuka honey stimulates immune cells via TLR4.* Journal of Leukocyte Biology 82, 1147-1155 DOI: 10.1189/jlb.1106683
2. Blair, S.E., et al. (2009) *The unusual antibacterial activity of medical-grade Leptospermum honey: antibacterial spectrum,resistance, and transcriptome analysis.* European Journal of Clinical Microbiology and Infectious Disease 28, 1199-1208 DOI: 10.1007/s10096-009-0763-z.
3. Molan, P.C., *Debridement of wounds with honey.* Journal of Wound Technology, 2009. 5: p. 12-17.
4. Gethin, G. and S. Cowman, *Manuka honey vs. hydrogel-a prospective, open label, multicentre, randomized controlled trial to compare desloughing efficacy and healing outcomes in venous ulcers.* Journal of Clinical Nursing, 2009. 18(3): p. 466-474.
5. Smith, T., K. Legel, and J.R. Hanft, *Topical Leptospermum honey (MEDIHONEY) in recalcitrant venous leg wounds: a preliminary case series.* Advances in Skin and Wound Care, 2008. 22(2): p. 68-71.
6. Allen, K.L., P.C. Molan, and G.M. Reid, *A survey of the antibacterial activity of some New Zealand honeys.* Journal of Pharmacyand Pharmacology, 1991. 43(12): p. 817-822.
7. Molan, P.C., Mode of Action, in Honey: A Modern Wound Management Product, R. White, R. Cooper, and P. Molan, Editors. 2006, Wounds UK Publishing: Aberdeen, UK.
8. Kumar, P., N. Fausto, and A.K. Abbas, eds. Robbins and Cotran Pathologic Basis for Disease. 7th ed. 2005, Elsevier: St. Louis, MO.

CASE 1 - PYODERMA GANGRENOSUM

A 54 year-old female with Pyoderma Gangrenosum presented to the outpatient clinic with a history of multiple wounds on the right lower extremity present for 2 years. Prior treatments, including compression bandages, calcium alginate dressings, biotherapy (maggots), negative pressure wound therapy, hyperbaric oxygen therapy, and collagenase, were ineffective. The patient refused immunosuppressive therapies.

Initially, ALH was applied to the larger wound and collagenase was applied to the smaller wound. Debridement proceeded more quickly in the wound treated with ALH, therefore collagenase was discontinued. ALH paste was initiated on 5/04/2009 and covered with an absorptive calcium alginate dressing three times per week. Light compression stockings were worn to minimize dependent edema.

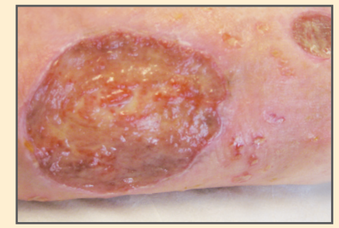

5/04/09
Full thickness wounds with a moderate to large amount of exudate, and slough. The proximal wound measured 10.0 cm x 9.0 cm x 0.2 cm; distal wound 3.0 cm x 3.0 cm x 0.5 cm.

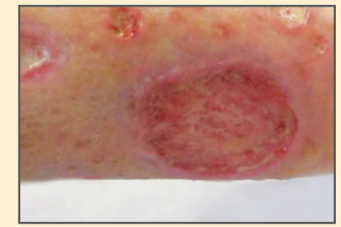

6/15/09
The proximal wound measured 4.5 cm x 3.0 cm x 0.2 cm and the distal wound measured 1.5 cm x 1.0 cm x 0.5 cm. Exudate, slough, and pain were decreased.

2/26/10
The proximal wound measures 3.0 cm x 2.5 cm x 0.1 cm and the distal wound is completely healed. Exudate is minimal, slough has been cleared and pain has been eradicated. The patient continues to apply ALH three times weekly with an absorbent calcium alginate cover dressing.

CASE 2 - RHEUMATOID ARTHRITIS

A 53 year-old male with a history of rheumatoid arthritis, morbid obesity, myocardial injury, and Hepatitis C, was admitted to the hospital with a new diagnosis of esophageal cancer. He was referred for evaluation of an MRSA positive foot wound of 2 ½ year duration. Prior treatments including silver calcium alginate dressings and compression bandaging, were ineffective. The patient was evaluated by rheumatology however he refused systemic therapy for the rheumatoid ulcer; chemotherapy for esophageal cancer was in progress. ALH paste was initiated on 5/04/2009, covered with an absorbent calcium alginate dressing, and secured with conforming gauze bandage. Compression bandaging was refused for edema management.

5/04/09
8.0 cm x 8.0 cm x 1.0 cm full thickness wound on the dorsal foot with large amounts of serous exudate, necrotic slough tissue, periwound erythema and pain.

6/03/09
After four weeks the wound measured 7.0 cm x 7.0 cm x 1.0 cm, exudate, necrotic slough, and periwound erythema were decreased. Increased granulation tissue and decreased pain were noted.

9/21/09
Complete healing was achieved despite continual chemotherapy for esophageal cancer.

CASE 3 - PRESSURE ULCER

A 56 year-old female with a history of abdominal compartment syndrome, cirrhosis of the liver, acute pancreatitis, congestive heart failure, malnutrition and hepatic encephalopathy, developed a sacral pressure ulcer after an episode of ischemia. Initially the ulcer presented as deep tissue injury which then evolved to a stage IV pressure ulcer. The patient was not a candidate for surgical debridement; collagenase was initiated and applied for three weeks however, progress toward debridement was slow. On 4/10/2009 ALH paste was initiated, and covered with an absorbent calcium alginate dressing daily. Minimal sharp debridement was performed as needed to remove loosened necrotic slough tissue.

Prior to ALH the patient reported constant, extreme pain (10/10); pain was managed with fentanyl patches, IV hydromorphone and topical lidocaine therapy and pressure relief (pressure redistribution mattress; side to side positioning for complete offloading).

4/10/09
Stage IV sacral pressure ulcer measuring 8.0 cm x 10.0 cm x 1.0 cm, with a moderate amount of serosanguinous exudate, periwound erythema, and adherent, loose, necrotic slough tissue in the wound base.

6/16/09
Wound measures 6.0 cm x 8.0 cm x 1.0 cm, with decreased exudates, and periwound erythema. Healthy granulation tissue is apparent with a small amount of exposed fascia. Patient's self-report of pain scores was gradually improving.

8/10/09
Complete healing was achieved with only small scab present.

*MEDIHONEY® Active Leptospermum Honey Absorbent Calcium Alginate Dressing, Derma Sciences, Inc., Princeton, New Jersey. Funding for cost associated with this poster provided by Derma Sciences, Inc. The information in this poster concerns a use that has not been approved or cleared by the US Food and Drug Administration.